

Egyptian Prosthodontic Association (EPA Newsletter)

Proximal Contact Stability of Fixed Restorations



Electronic Newsletter

Volume 2, Issue 10

October 2023

The shifting of teeth next to fixed dental prostheses is a confusing and complex phenomenon that may be caused by normal alveolar development, functional occlusal loading, para-functional occlusal activities, or multifactorial aetiology¹. Even though it's crucial to understand the potential causes of adjacent tooth movement, the mere fact that it does happen is a key factor to take into account in restoration treatment planning and maintenance protocols. Wide-ranging clinical effects result from proximal contact opening caused by variable relative movement.

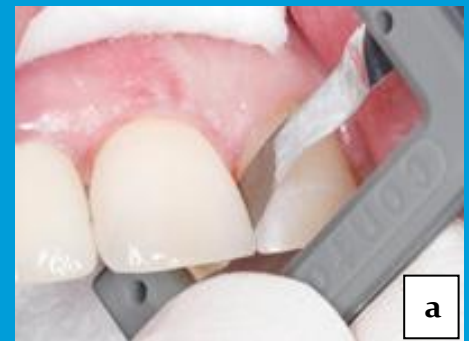Proximal Contact Stability in the Short-Term

Prosthetic restorations should maintain close proximal contact with the neighbouring teeth in order to protect periodontal structures. Practitioners have, however, observed a high prevalence proximal contact loss between fixed restorations and neighbouring teeth.² The maximum force required to remove a metal strip from between the restoration and the neighbouring tooth served as the standard by which the tightness of proximal contact has to be established (Figure 1a, b).

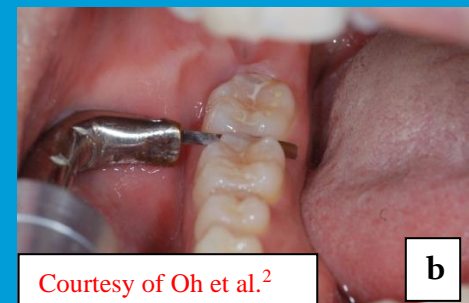Proximal contact between restorations and natural teeth should be made to be tighter than that between natural teeth in order to prevent food impaction over time (Figure 2). After three months, the mesial and distal aspects of the contact tightness will significantly decrease, reaching a level comparable to that of adjacent natural teeth.³

Prevalence of Proximal Contact Loss Over the Long-Term

Figuring out the reason for proximal contact loss between fixed dental prostheses and nearby natural teeth has proven challenging. Although mesial drifting is the most common movement, distal drifting is also a possibility.⁴ Compared to only 5% of the distal contacts, 27% of the mesial contacts were categorised as being open in patients who received fixed dental prostheses over a 10-year period and who had returned for routine follow-up care after restoration (Figure 3).⁵



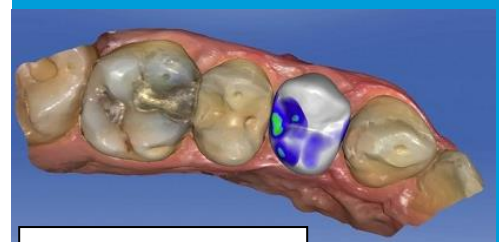
a



b

Courtesy of Oh et al.²

Fig. 1a & b: Tightness and strength of proximal contact measured using a metal strip.



Courtesy of Shi et al.³

Fig. 2: Initial tightening of proximal contact.

As it has become increasingly clear that the proximal contact between fixed dental restorations and nearby natural teeth will change over time, it is important to know that there are main factors that have the biggest impact on this phenomenon, starting from food impaction, more frequent use of an interdental brush, and more than 5 years of function were significantly linked to loss of contact.⁶ Proximal contact modification should be expected, even in the short term. This may be a hint to plan for a slightly tense proximal contact during restoration, particularly in the mesial side.⁷

Contact Stability Around Single Implant Restorations

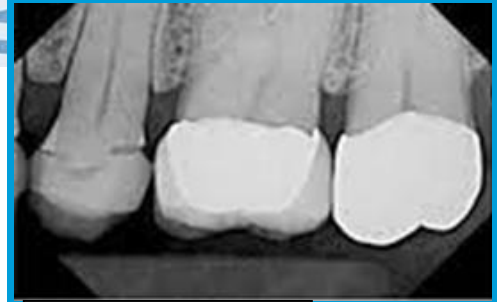Single-implant crowns present a unique challenge. These restorations, which are frequently implanted in younger patients, may be subject to movement as a result of skeletal development over time with 30% of patients exhibiting an occlusal movement of greater than 1 mm after 2 years of use, which will in turn affect the proximal stability. (Figure 4).^{8,9}

Commonness of Proximal

Contact Loss and Consequences

Food impaction is strongly correlated with proximal contact loss between fixed restorations and adjacent natural teeth, which may be detrimental to the periodontium's health. The incidence between the maxilla and the mandible showed little variation. While there was no difference in incidence between restorations placed next to vital and non-vital teeth, the rate of proximal contact loss increased with the length of time the restoration had been in use.¹⁰

A healthy dentition with proper occlusal and proximal contacts helps to stabilize and maintain the integrity of teeth. It prevents further aggravation of the periodontium, the occurrence of pain and prosthesis failure. The prosthesis evaluation both clinically and radiographically before final cementation, proper use of interdental brushes and efficient oral hygiene measures are the main factors affecting proximal contact stability.



Courtesy of Ren et al.⁵

Fig. 3: Higher possibility of mesial contact instability after fixed restorations.

References

- 1- Hansen PA, Atwood A, Shanahan M, Beatty M. The accuracy of clinician evaluation of interproximal contacts using different methods. *J Prosthet Dent*. 2020;123(2):284-289.
- 2- Oh SH, Nakano M, Bando E, Shigemoto S, Kori M. Evaluation of proximal tooth contact tightness at rest and during clenching. *J Oral Rehabil*. 2004;31(6):538-545.
- 3- Shi J-Y, Zhu Y, Gu Y-X, Lai H-C. Proximal contact alterations between implant-supported restorations and adjacent natural teeth in the posterior region: a 1-year preliminary study. *Int J Oral Maxillofac Implants*. 2019;34:165-168.
- 4- Bento VAA, Gomes JML, Lemos CAA, Limirio JPJO, Rosa CDDRD, Pellizzer EP. Prevalence of proximal contact loss between implant-supported prostheses and adjacent natural teeth: A systematic review and meta-analysis. *J Prosthet Dent*. 2023;129(3):404-412.
- 5- Ren S, Lin Y, Hu X, Wang Y. Changes in proximal contact tightness between fixed implant prostheses and adjacent teeth: a 1-year prospective study. *J Prosthet Dent* 2016;115:437-440.
- 6- Oh WS, Oh J, Valcanaia AJ. Open Proximal Contact with Implant-Supported Fixed Prostheses Compared with Tooth-Supported Fixed Prostheses: A Systematic Review and Meta-analysis. *Int J Oral Maxillofac Implants*. 2020;30(6):e99-e108.
- 7- Liang C-H, Nien C-Y, Chen Y-L, Hsu K-W. The prevalence and associated factors of proximal contact loss between implant restoration and adjacent tooth after function: a retrospective study. *Clin Implant Dent Relat Res* 2020;22:351-358.
- 8- Boon L, De Mars G, Favril C, Duyck J, Quirynen M, Vandamme K. Esthetic evaluation of single implant restorations, adjacent single implant restorations, and implant-supported fixed partial dentures: A 1-year prospective study. *Clin Implant Dent Relat Res*. 2020;22(1):128-137.
- 9- Winitzky N, Naimi-Akbar A, Nedelcu R, et al. 3-D tooth movement adjacent to single anterior implants and esthetic outcome. A 14- to 20-year follow-up study. *Clin Oral Implants Res* 2021;32:1328-1340.
- 10- Manicone PF, De Angelis P, Rella E, et al. Proximal contact loss in implant-supported restorations: a systematic review and metaanalysis of prevalence. *J Prosthodont* 2021; doi:10.1111/jopr.13407.

Egyptian Prosthodontic Association (EPA)

Address: 15 Ahmed Abo El-Ela St. – 8th district Nasr City, Cairo Egypt.

Mobile : 010 28203484 (Calls & Whatsapp) Phone: 02 26705035